

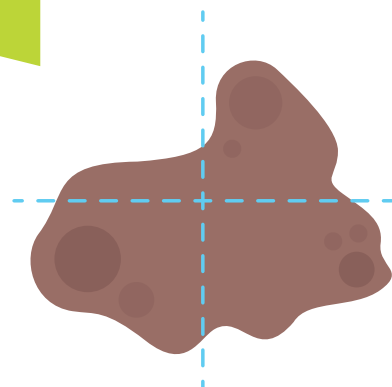
IRREGULAR OR ASYMMETRIC PIGMENTED LESIONS

**BE
ALERT!**

**TO IRREGULAR OR
ASYMMETRIC MOLES**

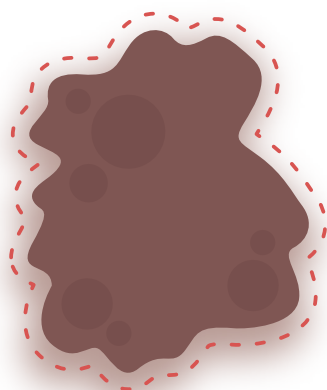
SHAPE

Is there
an irregular
horizontal
or vertical
shape?




BORDER

Is there
an irregular
border?



COLOUR

Does the
lesion have
multiple
colours?



ARCHITECTURE

Order vs
disorder

Are there multiple structures on dermoscopy
e.g. white streaks, dots, different pigment patterns?



BEHAVIOUR

Has the patient
reported that the
lesion has changed?

Is the lesion:
Changing in size, shape or colour?

